

Is gynecomastia related to the disease characteristics and prognosis in testicular germ cell tumor patients?

Ahmet Veysel Polat 

Mesut Öztürk 

İlkay Çamlıdağ 

Behiç Akyüz 

PURPOSE

We aimed to assess the relationship between gynecomastia and tumor markers, histologic subtypes, and prognosis in patients with testicular germ cell tumors.

METHODS

This study included 73 testicular germ cell cancer patients with pretreatment chest, abdomen and pelvis computed tomography (CT) scans and tumor markers (β -human chorionic gonadotropin [β -hCG], lactate dehydrogenase [LDH], α -fetoprotein [AFP]). The volumetric analysis of the breast glandular tissue, the presence of gynecomastia and metastatic disease were determined using CT scans. Patients were classified according to the International Germ Cell Cancer Collaborative Group (IGCCCG) prognostic classification. The association between gynecomastia, breast glandular tissue volume, tumor markers, metastatic disease, and disease prognosis were evaluated.

RESULTS

Thirty-four of the patients (46.6%) had gynecomastia. A breast volume cutoff value of 0.78 cm³ to diagnose gynecomastia led to 85% sensitivity and 95% specificity. Serum β -hCG level correlated with the breast glandular tissue volume weakly ($r=0.242$, $P=0.039$). Gynecomastia was more common in patients with elevated β -hCG levels ($P=0.047$), and was not associated with pulmonary, nonpulmonary distant, or nodal metastases ($P=0.378$, $P=0.884$, $P=0.333$, respectively). No significant association was found between the disease prognosis and gynecomastia ($P=0.556$).

CONCLUSION

Gynecomastia was common among testicular germ cell cancer patients with elevated β -hCG. However, it was not associated with metastatic disease and prognosis.

Gynecomastia is the benign enlargement of the male breast glandular tissue due to ductal proliferation and is the most common disease of male breasts (1). It may be physiologic in the neonatal period, during puberty, and in the elderly, or it can be secondary to certain pathologic processes, including hepatic dysfunction, adrenal tumors, hyperthyroidism, infertility, sexual dysfunction, medications, and rarely, testicular cancer (2–7). Approximately 2%–4% of gynecomastia cases are related to testicular tumors, and 7%–11% of patients with testicular tumors present with gynecomastia as the initial symptom (1, 4, 8–10). Testicular cancers presenting with gynecomastia are reported to have a worse prognosis, but this is needed to be confirmed with recent studies (4, 11, 12).

Testicular cancer accounts for 1%–1.5% of all male cancers and 5% of all urologic neoplasms (13, 14). The peak age ranges from 25 to 29 years, although it may be seen in all age groups (15). Staging of the disease is based on the levels of serum tumor markers and a staging chest abdominopelvic computed tomography (CT) for the determination of metastatic spread. Tumor markers for testicular cancer are α -fetoprotein (AFP), lactate dehydrogenase (LDH), and β -human chorionic gonadotropin (β -hCG). The International Germ Cell Cancer Collaborative Group (IGCCCG) made a prognostic classification for these patients based on the levels of tumor markers and the presence of nonpulmonary metastases on staging CT (16).

From the Department of Radiology (A.V.P., M.Ö. ✉ dr.mesutozturk@gmail.com, İ.Ç.), Ondokuz Mayıs University School of Medicine, Samsun, Turkey; Clinic of Radiology (B.A.), Gölcük Necati Çelik State Hospital, Kocaeli, Turkey.

Received 19 June 2018; revision requested 17 July 2018; last revision received 10 August 2018; accepted 19 August 2018.

Published online 8 March 2019.

DOI 10.5152/dir.2019.18297

You may cite this article as: Polat AV, Öztürk M, Çamlıdağ İ, Akyüz B. Is gynecomastia related to the disease characteristics and prognosis in testicular germ cell tumor patients? *Diagn Interv Radiol* 2019; 25:189–194.

In this study, our aim was to assess the relationship between gynecomastia and tumor markers, histologic subtypes, and prognosis in patients with testicular germ cell cancers. We hypothesized that any relationship between gynecomastia, histologic subtypes and the disease prognosis might have a considerable effect on patient management. To the best of our knowledge, our study was the first one measuring the breast glandular tissue volume quantitatively for the assessment of gynecomastia in patients with testicular germ cell cancer.

Methods

This retrospective study was approved by our institutional ethics committee and the requirement for informed consent was waived due to the nature of the study. The Standards for the Reporting of Diagnostic Accuracy Studies guidelines were used (17).

Study population

A retrospective search of our hospital's database revealed 167 male patients with testicular cancer diagnosed from January 2010 through April 2018. Patients whose pretreatment chest and abdominopelvic CT scan and tumor markers (β -hCG, LDH, AFP) were available were included in this study. Tumor markers of all patients were assessed before surgery. Chest and abdominopelvic CT scans were performed before or after orchiectomy, with a maximal interval period of one month to the surgery (14.6 ± 9.9 days; range, 0–30 days). We excluded two patients because of the diagnosis of non-germ cell testicular cancer (testicular lymphoma). Patients with missing data (CT examination, $n=57$; laboratory measurements, $n=22$; pa-

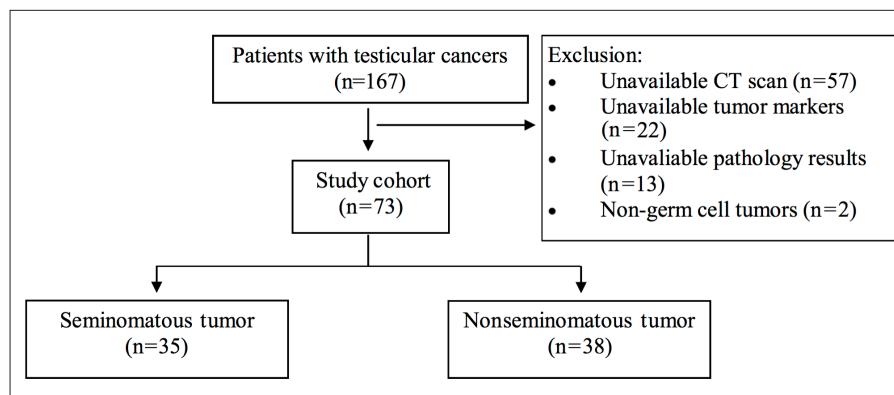


Figure 1. Flowchart of the study.

thology results, $n=13$) were also excluded. Overall, 73 patients with testicular germ cell cancers met the enrollment criteria (Fig. 1). The mean age of the study population was 30.21 ± 8.63 years (range, 14–53 years).

Data concerning age, histologic subtype, laterality of the tumor, and levels of tumor markers for each patient were collected from the hospital database. The normal values of tumor markers at our laboratory were 0–5 IU/L for β -hCG, 0–480 U/L for LDH, and 0–5 IU/mL for AFP. Patients were classified according to their tumor marker levels as having normal or elevated tumor markers. Patients were also classified according to the IGCCCG prognostic classification system for metastatic germ cell cancers based on laboratory measurements and the presence of metastatic disease (16).

CT examination

Chest, abdomen and pelvis CT scans of all patients were obtained for disease staging purposes. CT studies were performed on two CT scanners: the Aquilion 16 CT system (Toshiba Medical Systems Corp.) and the Discovery CT750 HD (GE Healthcare). Patients were administered intravenous (90–120 mL iodinated contrast agent) and oral (25 mL iodinated contrast agent diluted in 1.5 L of water) contrast agents.

Thoracic CT scans were reviewed by two radiologists for the presence of gynecomastia. The presence of gynecomastia was consensually determined based on visual assessments of both breasts on the CT scans. Images were reviewed for the presence or absence of gynecomastia, and, if present, the pattern of gynecomastia was identified (nodular, dendritic, or diffuse) according to a previously described classification (18) (Fig. 2).

A fourth-year radiology resident measured the breast glandular tissue volumes

quantitatively using the OsiriX software (version 3.8.1, Pixmeo) and its volumetric function. This was based on the Cavalieri principle in which the area was measured in serial slices by tracing the borders of the gynecomastia and multiplied by the slice thickness. The volume was calculated in cm^3 and a three-dimensional (3D) diagram of the breast glandular tissue volume was generated for both breasts (Fig. 3). The maximum breast glandular tissue volume was used for the statistical analysis. Data regarding the clinical assessment of gynecomastia of all patients were unavailable.

The radiology resident also measured the axial diameter of the breast glandular tissue at the level of nipple. Patients were classified as having gynecomastia if at least one of the axial breast glandular tissue diameters was more than 20 mm and another gynecomastia classification was done (12).

A body imaging radiologist reviewed the chest, abdomen and pelvis CT scans for the presence of pulmonary, nodal, and nonpulmonary distant metastasis. Lymph nodes up to 10 mm in short diameter were accepted as non-neoplastic (19).

Statistical analysis

Statistical analyses were performed with SPSS version 18.0 (SPSS Inc. for Windows). Data are presented as mean and standard deviation or median and range for continuous variables. Kolmogorov-Smirnov tests were used to assess normal distribution of the data. Pearson chi-square and Fisher exact tests were used to compare gynecomastia, metastatic spread, tumor marker status, and disease prognosis. Student's *t* test and Mann-Whitney *U* test were used to compare differences of the continuous variables in independent groups. Spearman's correlations were used to evaluate the re-

Main points

- Gynecomastia prevalence is higher in patients with elevated serum β -human chorionic gonadotropin (β -hCG) levels.
- Gynecomastia is more common in testicular germ cell tumor patients with nonseminomatous histology.
- There is a weak correlation between serum β -hCG level and breast glandular volume.
- Presence of gynecomastia appears to be independent of the disease prognosis.
- Volumetric analysis of breast glandular tissue volume may be a new tool to quantify gynecomastia.

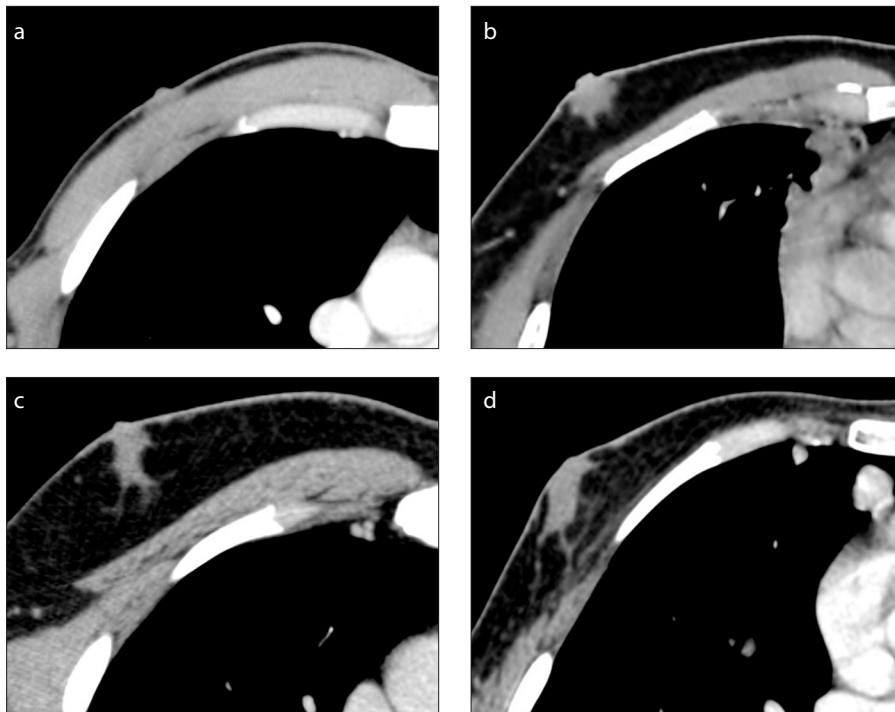


Figure 2. a–d. CT classification of breast glandular tissue. Examples of patients without gynecomastia (a) and nodular (b), dendritic (c), and diffuse (d) types of gynecomastia are shown.

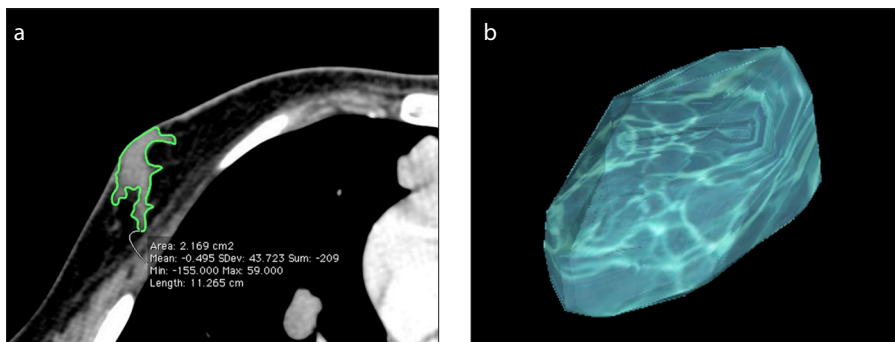


Figure 3. a, b. Panel (a) shows measurement of the breast glandular tissue area by tracing the borders of the gynecomastia; panel (b) shows a 3D diagram reconstruction of the glandular tissue.

relationship between β -hCG levels and breast glandular volumes. $P < 0.05$ was indicative of statistically significant difference. Receiver operating characteristic (ROC) curve was constructed to determine a volumetric cutoff value for breast glandular tissue corresponding to the intersection of sensitivity and specificity curves by maximizing the Youden index (Youden index=sensitivity+specificity-1).

Results

Demographic and clinical data of the study cohort are summarized in Table 1. Thirty-five patients had seminomatous testicular tumors, whereas 38 patients had nonseminomatous testicular tumors. The

nonseminomatous tumors included 5 embryonal carcinomas, 2 choriocarcinomas, 3 endodermal sinus tumors, and 28 mixed germ cell tumors. The mixed germ cell tumor group consisted of 25 embryonal carcinoma, 20 teratoma, 17 endodermal sinus tumor, 5 choriocarcinoma, and 8 seminoma components. Twenty-three patients had nodal, 14 patients had pulmonary and 4 patients had nonpulmonary visceral metastases. All pulmonary and nonpulmonary visceral metastases were seen in patients with nonseminomatous testicular tumors ($P < 0.001$ and $P = 0.116$, respectively). Nodal metastases was significantly more common in patients with nonseminomatous tumors ($P = 0.011$). According to IGC-

CCG classification, 58 patients had good, 11 patients had intermediate, and 4 patients had poor prognosis. Intermediate and poor prognosis were more common in patients with nonseminomatous tumors ($P = 0.003$). Three patients died 2, 13, and 19 months after the diagnosis. All of these patients had nonseminomatous testicular tumor and all of them had gynecomastia according to visual assessment (breast volumes: 1.26, 2.53, and 11.93 cm^3). Median follow-up of the remaining patients was 18 months (range, 1–74 months) and no other deaths occurred.

According to visual assessment, gynecomastia was present in 34 of the 73 patients (46.6%) with testicular germ cell tumor. Eight patients had nodular, 22 patients had dendritic, and 4 patients had diffuse gynecomastia. The median maximum breast glandular tissue volume was 1.83 cm^3 (range, 0.47–11.93 cm^3) for patients with gynecomastia and 0.31 cm^3 (range, 0.01–0.85 cm^3) for patients without gynecomastia ($P < 0.001$). Selecting a cutoff value of 0.78 cm^3 for gynecomastia diagnosis led to 85% sensitivity and 95% specificity (AUC, 0.975; 95% CI, 0.948–1.002; $P < 0.001$).

We found a significant association between gynecomastia and elevated serum β -hCG levels. Twenty-one of 36 patients (58.3%) with elevated β -hCG and 13 of 37 patients (35.1%) with normal β -hCG had gynecomastia ($P = 0.047$). There was no relationship between the gynecomastia type and presence of elevated serum β -hCG ($P = 0.503$). Serum β -hCG level correlated weakly with the maximum breast glandular tissue volume ($r=0.242$, $P = 0.039$). Positive serum AFP and LDH levels were not associated with gynecomastia ($P = 0.743$ and $P = 0.148$, respectively).

The gynecomastia prevalence was significantly higher in patients with nonseminomatous germ cell tumors (22/38 vs. 12/35, $P = 0.043$). Gynecomastia was not associated with pulmonary, nodal, or nonpulmonary visceral metastases ($P = 0.378$, $P = 0.884$, $P = 0.333$, respectively). There was no significant association between the disease prognosis and the presence of gynecomastia ($P = 0.556$) (Table 2). We assessed the relationship of gynecomastia, metastasis, and disease prognosis within subgroups according to seminomatous and nonseminomatous histology. The statistical analysis again demonstrated no significant relationship between gynecomastia and disease prognosis ($P = 1.000$ and $P = 0.715$

Table 1. Demographic and clinical data of the study population

Characteristics	Whole study population	Patients with seminomatous tumors	Patients with nonseminomatous tumors	<i>P</i> ^a
Age (years) ^b	30.21±8.63 (14–53)	33.71±8.58 (14–53)	26.97±7.41 (14–50)	0.001
β-hCG (IU/L) ^c	5.55 (0–975364)	1.14 (0–8534)	48.05 (0–975364)	<0.001
LDH (U/L) ^c	282 (146–2090)	279 (150–1866)	291 (146–2090)	0.443
AFP (IU/mL) ^c	3.07 (0.23–13476)	1.06 (0.23–8.1)	49.6 (0.9–13476)	<0.001
Follow-up period (months) ^c	18 (1–74)	17 (1–74)	19 (2–58)	0.210
Nodal metastases ^d	23	6	17	0.011
Pulmonary metastases ^d	14	0	14	<0.001
Nonpulmonary visceral metastases ^d	4	0	4	0.116
Prognostic classification				0.003
Good prognosis ^d	58	33	25	
Intermediate or poor prognosis ^d	15	2	13	

β-hCG, β-human chorionic gonadotropin; LDH, lactate dehydrogenase; AFP, α-fetoprotein.

^aDerived from the comparison of patients with seminomatous tumors and patients with nonseminomatous tumors; ^bMean ± standard deviation and range in parenthesis; ^cMedian value and range in parenthesis; ^dTotal number of cases.

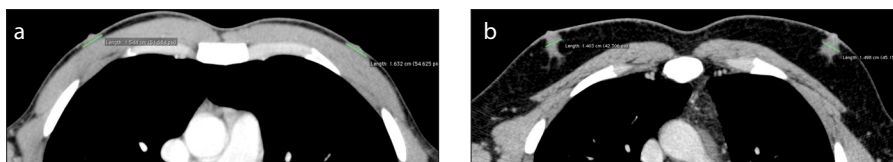


Figure 4. a, b. Comparison of two patients with similar axial breast glandular tissue diameters at the nipple level: (a) patient without gynecomastia, (b) patient with dendritic gynecomastia. Although the axial diameters are the same, more glandular tissue is seen in panel (b).

respectively). Pulmonary, nodal, or nonpulmonary visceral metastases were not associated with gynecomastia in patients with nonseminomatous tumors ($P = 0.943$, $P = 0.578$, $P = 0.624$, respectively).

We measured the maximum axial diameter of the breast glandular tissue and performed statistical analysis. Patients whose breast glandular tissue diameter was more than 20 mm were classified as having gynecomastia. According to this criterion, gynecomastia was present in 22 of 73 patients (30.1%). There was a significant association between gynecomastia and elevated serum β-hCG level ($P = 0.034$), and the breast glandular tissue diameter was not associated with serum β-hCG level ($r=0.221$,

$P=0.073$). Gynecomastia was not associated with pulmonary, nodal, or nonpulmonary visceral metastases ($P = 0.747$, $P = 0.970$, $P = 0.579$, respectively). There was no significant association between the disease prognosis and the presence of gynecomastia ($P = 0.361$). We assessed the relationship of gynecomastia and disease prognosis within subgroups according to seminomatous and nonseminomatous histology, which also demonstrated no significant relationship ($P = 0.365$ and $P = 0.927$, respectively). Pulmonary, nodal, or nonpulmonary visceral metastases were not associated with gynecomastia in patients with nonseminomatous tumors ($P = 0.717$, $P = 0.254$, and $P = 1.000$, respectively).

Discussion

Our study results confirmed an association between elevated β-hCG levels and gynecomastia. However, we found a weak correlation between the breast glandular tissue volume and serum β-hCG level. Gynecomastia was more common in patients with nonseminomatous germ cell tumors in which the prevalence of elevated serum β-hCG was also more common.

Although gynecomastia is defined as the enlargement of breast glandular tissue, an objective diagnostic criteria or quantitative measurement system is not yet available. Radiologic features are well defined on mammography, CT, ultrasonography, and magnetic resonance imaging (MRI), based on the visual assessment of breast glandular tissue (18, 20, 21). Three mammographic patterns have been described: nodular, dendritic, and diffuse types. Sonnenblick et al. (21) reported that the CT appearance of gynecomastia correlates well with the mammographic appearance, and that the CT scan may be sufficient for diagnosis. However, some authors claim that a clinical evaluation without imaging may be sufficient for diagnosis and define gynecomastia as a firm, palpable, subareolar tissue greater than 2 cm (1, 22). Klang et al. (12) used CT images to evaluate gynecomastia and defined gynecomastia as axial diameter of the breast glandular tissue more than 2 cm. In our belief, the diagnosis of gynecomastia by visual assessments may be more appropriate than measuring the axial diameter on CT scans. While axial diameters of breast glandular tissue may be the same between two patients, gynecomastia may still be present although the diameter is less than 2 cm because of a vertical growth pattern of the tissue (Fig. 4). To overcome this limitation, we diagnosed gynecomastia visually, as previously described, and measured its quantity by calculating the breast glandular tissue volume. A cutoff value of 0.78 cm³ for diagnosing gynecomastia led to 85% sensitivity and 95% specificity. This finding suggests that volumetric analysis can also be used to diagnose gynecomastia. More studies with larger populations are needed to determine a more precise volumetric cutoff value.

Gynecomastia may be the presenting symptom of patients with testicular tumors (5–7). During the early stages of a testicular tumor with a nonpalpable testicular mass, gynecomastia may be the first sign of the

Table 2. Comparison of gynecomastia and disease characteristics

Characteristics	Gynecomastia (n) Visual analysis ^a			Gynecomastia (n) Axial diameter ^b		
	Absent (%)	Present (%)	<i>P</i>	Absent (%)	Present (%)	<i>P</i>
Testis			0.459			0.734
Right	24 (57.1)	18 (42.9)		30 (71.4)	12 (28.6)	
Left	15 (48.4)	16 (51.6)		21 (67.7)	10 (32.3)	
β-hCG			0.047			0.034
Elevated	15 (41.7)	21 (58.3)		21 (58.3)	15 (41.7)	
Normal	24 (64.9)	13 (35.1)		30 (81.1)	7 (18.9)	
LDH			0.148			0.067
Elevated	6 (37.5)	10 (62.5)		8 (50)	8 (50)	
Normal	33 (57.9)	24 (42.1)		43 (75.4)	14 (24.6)	
AFP			0.743			0.211
Elevated	18 (51.4)	17 (48.6)		22 (62.9)	13 (37.1)	
Normal	21 (55.3)	17 (44.7)		29 (76.3)	9 (23.7)	
Tumor histology			0.043			0.070
Seminomatous	23 (65.7)	12 (34.3)		28 (80)	7 (20)	
Nonseminomatous	16 (42.1)	22 (57.9)		23 (60.5)	15 (39.5)	
Pulmonary metastases			0.378			0.747
Present	6 (42.9)	8 (57.1)		9 (64.3)	5 (35.7)	
Absent	33 (55.9)	26 (44.1)		42 (71.2)	17 (28.8)	
Nodal metastases			0.884			0.970
Present	12 (52.2)	11 (47.8)		16 (69.6)	7 (30.4)	
Absent	27 (54)	23 (46)		35 (70)	15 (30)	
Nonpulmonary visceral metastases			0.333			0.579
Present	1 (25)	3 (75)		2 (50)	2 (50)	
Absent	38 (55.1)	31 (44.9)		49 (71)	20 (29)	
Prognosis			0.556			0.361
Good	32 (55.2)	26 (44.8)		42 (72.4)	16 (27.6)	
Intermediate or poor	7 (46.7)	8 (53.3)		9 (60)	6 (40)	

^aGynecomastia diagnosis was made based on visual analysis; ^bGynecomastia diagnosis was made based on axial diameter of breast glandular tissue; β-hCG, β-human chorionic gonadotropin; LDH, lactate dehydrogenase; AFP, α-fetoprotein.

clinically occult cancer due to endocrine manifestations. Therefore, some authors recommend testicular ultrasound and laboratory measurements of serum tumor markers in patients presenting with gynecomastia (1, 8, 23). The prevalence of gynecomastia among patients with testicular

tumors was reported to be 7%–11% at the initial presentation (4, 8, 10). However, these reports are based on clinically symptomatic diseases. In our study, we investigated the presence of gynecomastia by interpreting thoracic CT studies that allowed better visualization of the breast glandular tissue com-

pared with physical examinations. Using visual analysis, gynecomastia was present in 34 of 73 patients (46.6%) with testicular cancer. If the axial diameter criterion was used, gynecomastia was present in 22 of 73 patients (30.1%). In a similar study carried out by Klang et al. (12), the prevalence of

CT-determined gynecomastia among patients with testicular cancer was 23.4%. This discordance may be due to the differences in the diagnostic criteria of gynecomastia. Although we do not know how many of our patients had symptomatic gynecomastia, the higher prevalence of gynecomastia in our study cohort may suggest that the prevalence of gynecomastia among patients with testicular cancer may be higher than previously reported, probably due to asymptomatic cases.

The pathogenesis of gynecomastia is marked by an increase in the estrogen to androgen ratio. This state may be due to the increased concentration of estrogen or estrogen precursors, or due to a decrease in the level of androgens. β -hCG induces the estradiol synthesis from the Leydig cells of the testis and the conversion of estrogen precursors to estrogen (9). It also has a direct proliferative effect on the male breast tissue (24). Our results also confirmed that elevated β -hCG was associated with gynecomastia. However, we found a weak correlation between the breast glandular tissue volume and the serum β -hCG level. Gynecomastia was more common among patients with nonseminomatous germ cell tumors, in which the elevated β -hCG was also more common.

In our study, the disease prognosis was not associated with gynecomastia. Testicular cancer patients presenting with gynecomastia have been reported to have poor prognosis (4). Tseng et al. (4) reported that four of eight patients presenting with gynecomastia died during a follow-up period of 60 months. The most likely etiology of symptomatic gynecomastia in patients with testicular germ cell tumor is the drastic level of β -hCG, which is also a poor prognostic factor in the IGCCCG classification.

In the IGCCCG prognostic classification system, nonpulmonary visceral metastasis is considered a prognostic factor, while pulmonary metastases are not involved in the classification. Therefore, in our study, we separated the hematogenous spread as pulmonary and nonpulmonary visceral metastases. We found no association between gynecomastia and any type of metastatic spread. Alternatively, Klang et al. (12) reported that an axial breast glandular tissue diameter of 2 cm to predict distant hematogenous metastasis yielded 75.1%

sensitivity and 80.5% specificity. Again, this discordance may be due to the use of different methods to assess gynecomastia in the two studies. However, when we used the same diagnostic criteria as Klang et al. (12), we again did not find a significant correlation between gynecomastia and any type of metastatic disease.

Our study has some limitations. First, it had a retrospective nature with inherent limitations. While we studied a limited number of patients, multicenter studies with larger populations are needed to validate these findings. In addition, we were unaware of the clinical findings of gynecomastia and we also did not have any histopathologic diagnosis of gynecomastia, which might serve as a golden standard of diagnosis. Metastatic disease was determined by CT rather than with a histopathologic diagnosis.

In conclusion, gynecomastia was more common in testicular germ cell cancer patients with elevated serum β -hCG levels. Breast glandular volume correlated weakly with serum β -hCG level. The presence of gynecomastia and the volume of breast glandular tissue were not associated with pulmonary, nodal, or distant hematogenous metastases and seemed to be independent of the disease prognosis.

Conflict of interest disclosure

The authors declared no conflicts of interest.

References

- Braunstein GD. Gynecomastia. *N Engl J Med* 1993; 328:490–495. [CrossRef]
- Cuhaci N, Polat SB, Evranos B, Ersoy R, Cakir B. Gynecomastia: clinical evaluation and management. *Indian J Endocrinol Metab* 2014; 18:150–158. [CrossRef]
- Hassan HC, Cullen IM, Casey RG, Rogers E. Gynaecomastia: an endocrine manifestation of testicular cancer. *Andrologia* 2008; 40:152–157. [CrossRef]
- Tseng A, Horning SJ, Freiha FS, Resser KJ, Hannigan JR JF, Torti FM. Gynecomastia in testicular cancer patients prognostic and therapeutic implications. *Cancer* 1985; 56:2534–2538.
- Kaptanis S, Parvanta L, Beltran L. Testicular seminoma presenting as unilateral gynecomastia. *Breast J* 2014; 20:424–426. [CrossRef]
- Kolitsas N, Tsambalas S, Dimitriadis F, et al. Gynecomastia as a first clinical sign of non-seminomatous germ cell tumor. *Urol Int* 2011; 87:248–250. [CrossRef]
- Harris M, Rizvi S, Hindmarsh J, Bryan R. Testicular tumour presenting as gynaecomastia. *BMJ* 2006; 332:837. [CrossRef]

- Daniels IR, Layer GT. Testicular tumours presenting as gynaecomastia. *Eur J Surg Oncol* 2003; 29:437–439. [CrossRef]
- Ismail AA, Barth JH. Endocrinology of gynecomastia. *Ann Clin Biochem* 2001; 38:596–607. [CrossRef]
- Hernes EH, Harstad K, Fossa SD. Changing incidence and delay of testicular cancer in southern Norway (1981–1992). *Eur Urol* 1996; 30:349–357. [CrossRef]
- Stepanaz AV, Samaan NA, Schultz PN, Holoye PY. Endocrine studies in testicular tumour patients with and without gynaecomastia: a report of 45 cases. *Cancer* 1978; 41:369–376. [CrossRef]
- Klang E, Rozendorn N, Raskin S, et al. CT measurement of breast glandular tissue and its association with testicular cancer. *Eur Radiol* 2017; 27:536–542. [CrossRef]
- Laguna MP, Pizzocaro G, Klepp O, Algaba F, Kissbenedek L, Leiva O. EAU guidelines on testicular cancer. *Eur Urol* 2001; 40:102–110. [CrossRef]
- Albers P, Albrecht W, Algaba F, et al. Guidelines on testicular cancer. *Eur Urol* 2005; 48:885–894. [CrossRef]
- Stevenson SM, Lowrance WT. Epidemiology and diagnosis of testis cancer. *Urol Clin North Am* 2015; 42:269–275. [CrossRef]
- Wilkinson PM, Read G. International Germ Cell Consensus Classification: a prognostic factor-based staging system for metastatic germ cell cancers. International Germ Cell Cancer Collaborative Group. *J Clin Oncol* 1997; 15:594–603. [CrossRef]
- Bossuyt PM, Reitsma JB, Bruns DE, et al. STARD 2015: an updated list of essential items for reporting diagnostic accuracy studies. *Radiology* 2015; 277:826–832. [CrossRef]
- Appelbaum AH, Evans GF, Levy KR, Amirkhan RH, Schumpert TD. Mammographic appearances of male breast disease. *Radiographics* 1999; 19:559–568. [CrossRef]
- Paño B, Sebastià C, Buñes L, et al. Pathways of lymphatic spread in male urogenital pelvic malignancies. *Radiographics* 2011; 31:135–160. [CrossRef]
- Madhukar M, Chetlun A. Multimodality imaging of benign and malignant male breast disease. *Clin Radiol* 2013; 68:e698–e706. [CrossRef]
- Sonnenblick EB, Salvatore M, Szabo J, Lee KA, Margolies LR. Incremental role of mammography in the evaluation of gynecomastia in men who have undergone chest CT. *AJR Am J Roentgenol* 2016; 207:234–240. [CrossRef]
- Stewart RAL, Howlett DC, Hearn FJ. Pictorial review: the imaging features of male breast disease. *Clin Radiol* 1997; 52:739–744. [CrossRef]
- Bowers SP, Pearlman NW, Jr, McIntyre RC, Finlayson, CA, Huerd S. Cost-effective management of gynecomastia. *Am J Surg* 1998; 176:638–641. [CrossRef]
- Carlson HE, Kane P, Lei ZM, Li X, Rao CV. Presence of luteinizing hormone/human chorionic gonadotropin receptors in male breast tissues. *J Clin Endocrinol Metab* 2004; 89:4119–4123. [CrossRef]